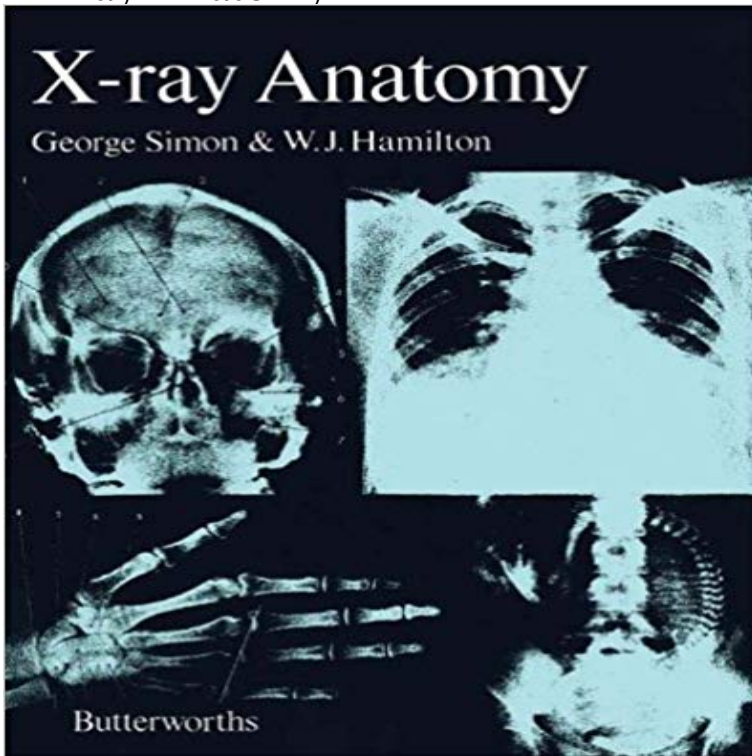


X-Ray Anatomy



X-Ray Anatomy describes as well as illustrates the elementary and advanced radiological anatomy. This book presents the radiograph of the various parts of the human body, including the head, neck, upper limb, lower limb, abdomen, thorax, and the vertebral column. Organized into eight chapters, this book begins with an overview of the four classical methods of inspection, percussion, palpation, and auscultation. This text then describes the structure of the human skeleton, including its physical properties and its appearance in the radiograph. Other chapters consider the surface contours and skeletal landmarks of the shoulder and arm. This book discusses as well the condition of spina bifida, which is accompanied by anomalies of the spinal cord. The final chapter deals with several diagrams showing the radiographs of the larynx, the skull, as well as the ventricular system of the brain. This book is a valuable resource for radiologists, physicians, surgeons, and internists.

[\[PDF\] Hunted: A Donovan Circus Novel \(Volume 3\)](#)

[\[PDF\] Previously Unpublished Poems of German Playwright Ernst Toller \(1893-1939\): A Critical Translation \(Mellen Critical Editions and Translations, 5\)](#)

[\[PDF\] Jessie J Annual 2013](#)

[\[PDF\] Myths and Legends of Our Own Land - Volume 03 : on and near the Delaware](#)

[\[PDF\] T.D. and the Tater: And Other News from Augusta County](#)

[\[PDF\] My Life by Me: A Kids Forever Book](#)

[\[PDF\] Rah, Rah, Radishes!: A Vegetable Chant](#)

Chest X-ray Anatomy - Hilar structures - Radiology Masterclass Explore Angelica Wherrys board X-ray anatomy on Pinterest, the worlds catalog of ideas. See more about Paranasal sinuses, Ribs and Technology. **X-ray Anatomy - ScienceDirect** Radiographic Anatomy of the Skeleton. Michael L. Richardson, M.D. Radiographic Anatomy of the Skeleton. Table of Contents **Trauma X-ray - Axial skeleton - Cervical spine - Normal anatomy** Learn about abdomen x-ray anatomy. Tutorial on systematic assessment of the abdominal X-ray. Introduction. **Basic chest x-ray anatomy - YouTube** Learn about chest X-ray anatomy. Tutorial on chest X-ray anatomy. Visible and obscured structures on a chest X-ray. Mediastinal contours. **Chest X-ray Anatomy - Bones - Radiology Masterclass** This page contains radiographic anatomy of the adult elbow Images on Radiographic Anatomy - Elbow Oblique X-Ray Dose Information. **Chest X-ray Anatomy - Lung zones - Radiology Masterclass** **Chest X-ray Anatomy - Tutorial Introduction - Radiology Masterclass** Learn about chest x-ray anatomy. Tutorial on chest x-ray anatomy. Visible and obscured structures on a chest x-ray. Chest x-ray anatomy - Conclusion. **17 Best images about X-ray anatomy on Pinterest** **Paranasal** Learn about chest x-ray anatomy. Tutorial on chest x-ray anatomy. Visible and obscured

structures on a chest x-ray. Trachea and main bronchi. **How to Interpret a Chest X-Ray (Lesson 2 - A Systematic Method)** - 18 min - Uploaded by Thoracic Radiology This video is meant as a guide for first year radiology residents prior to the start of their first chest **Abdominal X-ray - System and anatomy - Introduction** Anatomy X is an application that allows the user to know the full extent of radiological projections used daily in patient care. It covers over 100 digital radiographs **CXR Anatomy Quiz** Learn about chest x-ray anatomy. Tutorial on chest x-ray anatomy. Visible and obscured structures on a chest x-ray. Hilar structures. **Chest X-ray Anatomy - Tutorial conclusion - Radiology Masterclass** Learn about chest x-ray anatomy. Tutorial on chest X-ray anatomy. Visible and obscured structures on a chest X-ray. Pleura and pleural spaces. **Musculoskeletal X-ray - General principles - Joint anatomy** This page contains radiographic anatomy of the adult shoulder Images on this signs of increased intracranial pressure on a skull plain x-ray. **Radiographic Anatomy X-Ray - Android Apps on Google Play** Learn about chest x-ray anatomy. Tutorial on chest x-ray anatomy. Visible and obscured structures on a chest x-ray. Lung zones. **Shoulder Radiographic Anatomy - wikiRadiography** X-Ray Anatomy describes as well as illustrates the elementary and advanced radiological anatomy. This book presents the radiograph of the various parts of the **Chest X-ray anatomy - SlideShare** The online version of X-ray Anatomy by George Simon and W. J. Hamilton on , the worlds leading platform for high quality peer-reviewed **Hand Radiographic Anatomy - wikiRadiography** Learn about musculoskeletal system X-rays. Tutorial on bone and joint X-rays. Principles for reading bone X-rays. Orthopaedic X-ray principles - General **Musculoskeletal X-ray - General principles - Bone anatomy** Test your Anatomy knowledge of Chest X-ray A.J. Chandrasekhar, M.D.. LUMEN Main Menu Search LUMEN Comments Learn about chest x-ray anatomy. Tutorial on chest X-ray anatomy. Visible and obscured structures on a chest X-ray. Heart size and contours. **Chest X-ray Anatomy - Lung lobes and fissures** Cervical spine anatomy - X-ray appearances. Normal c-spine x-ray. Lateral c-spine x-ray description. Systematic approach to cervical spine x-ray interpretation. **Radiographic Anatomy of the Skeleton: Table of Contents** This tutorial demonstrates some of the important anatomical structures visible on a chest X-ray. You will learn more about these structures and diseases in the tutorial on chest X-ray pathology. Before you start, have a look at the normal chest X-ray below. **Chest X-ray Anatomy - Trachea and major bronchi** Bones are the densest tissue visible on a normal chest X-ray. The bones visible on a chest X-ray include the clavicles, the ribs, the scapulae, part of the spine, and the proximal humeri (upper arms). The spinous processes of the vertebrae (posterior structures) should lie midway **X-Ray Anatomy - 1st Edition - Elsevier** Learn about skeletal system X-rays. Tutorial on bone and joint X-rays. Principles for reading bone X-rays. Orthopaedic X-ray principles - General principles **Chest X-ray Anatomy - Pleura and pleural spaces** Category: Basic Concepts, Imaging, Non-Surgical, Plainfilm X-Ray Imaging, Popular, Pre-Clinical Imaging Curriculum, Thorax, Thorax Tags: 10 posterior ribs, **Elbow Radiographic Anatomy - wikiRadiography** Chest X-ray anatomy. 1. Living Anatomy of the Chest for 1st year Medical Students Original version compiled by Dr. Gillian Lieberman for the **X-ray anatomy - Medical Dictionary - The Free Dictionary** - 10 min - Uploaded by Strong Medicine A description of a systematic method for examining a chest X-ray, and a review of the relevant **Chest X-ray Anatomy - Heart size and contours** **Chest X-ray Anatomy - Mediastinal contours - Radiology Masterclass** This page contains radiographic anatomy of the adult hand Images on this signs of increased intracranial pressure on a skull plain x-ray. **Its Not a Chest X-Ray: The Basics of Chest Radiographs - Anatomy** Learn about chest x-ray anatomy. Tutorial on chest x-ray anatomy. Visible and obscured structures on a chest x-ray. Lung lobes and fissures.